

A 1-Year Old Girl with Severe Malnutrition, Bloody-Mucoid Diarrhoea and Fever

Postmortem Study Case - 2 of 1992

PRESENTATION OF THE CASE

A 1-year old, severely malnourished girl weighing 5.98 kilogram was admitted to the hospital with a history of bloody-mucoid diarrhoea, fever, and loss of appetite for 5 days.

The mother of this girl said that the child had no previous history of abdominal pain, nausea, vomiting, diarrhoea, haematemesis, and melaena. About a week ago the mother noticed appearance of loose stools which contained blood and mucus. Except being malnourished, the child did not suffer from major illnesses during the last 1-year. The bowel movements were associated with straining and passage of blood and mucus 5-6 times a day for the last 5 days. There was no history of vomiting. The dysenteric symptoms were associated with low grade, persistent fever without any chills, rigor, and convulsions. During the recent illness the child was treated at home by giving 1 litre (2 packets) of oral rehydration solution along with some unspecified medication. Family history revealed that the child was born normally at home and was living in an unhygienic environment with poor sanitation. The child was immunized against tuberculosis, polio and measles at appropriate ages. For the first 3 months of life the girl was breastfed and then supplemented with dilute formula milk and rice powder. Family histories about the siblings of the girl could not be elicited at the time of admission.

On physical examination, the girl appeared undernourished, lethargic, and mildly dehydrated. Her radial pulse was imperceptible and the brachial pulse was low in volume but regular in rhythm (120/minute). Rectal temperature was 37°C, and respiration was regular with a rate of 40/minute. Her body weight was 5.98 kg which is 62% of the 50th centile of the NCHS median standard for weight for age. There was no pallor, cyanosis or jaundice. However, there was bilateral pitting oedema of feet.

Abdominal examination disclosed a moderately distended abdomen with ascitis. There was slightly decreased bowel sounds but no definite tenderness; the liver and spleen were not felt, and no masses were detected. Rectal examination did not reveal any intussusception or polyps. The head, neck, lungs and heart were normal. Neurologic examination did not reveal any abnormality. There was severe

hypoglycaemia on admission too low to be as determined from a finger blood specimen by the Glucocheck Machine (Reflolux-S, Boehringer, Germany).

The major clinical findings on admission were; dysenteric illness, severe malnutrition with pedal oedema, anorexia, low grade fever, poor peripheral pulse without significant dehydration, lethargy, and severe hypoglycaemia. On the basis of the above clinical findings a provisional diagnosis of invasive diarrhoea (shigellosis?) with protein energy malnutrition (Kwashiorkor) and septic shock with hypoglycaemia was made.

On admission the following laboratory investigations were done. The haematocrit was 27 percent; the white-cell count was 12,800/cmm with 48 percent neutrophils, 2 percent band-cells, 44 percent lymphocytes, 2 percent monocytes, 2 percent eosinophils, and 2 percent metamyelocytes. The red cells were hypochromic with 0.2 percent fragmented cells. The platelet count was 90,000/cmm. Serum electrolyte concentrations determined before administering intravenous fluids showed 129 millimol per litre of sodium, 2.81 millimol per litre of potassium, 105 millimol per litre of chloride and 19.4 millimol per litre of total carbon dioxide (TCO₂). Total serum protein was 42 gram per litre and albumin was 20.3 gram per litre.

Results of urinalysis revealed an alkaline urine with mildly positive reaction (1+) for protein, bile salt and bile pigment. The urine contained 1-2 red cells, 8-10 pus cells, and 3-5 epithelial cells per high power field. X-Ray films of the chest showed that the cardiomeastinal silhouette was normal but there was patchy infiltrations in the upper zone of the right lung with diffuse opacity at the left lung base obliterating the left cardiophrenic angle suggesting collection of pleural fluid. X-Ray films of the abdomen taken with the patient supine and upright disclosed gas and stool within the dilated loops of the large bowel; no free intraperitoneal air under the diaphragm or any calcification were observed; slight elevation of the right diaphragmatic dome was noted.

Blood culture taken on admission subsequently revealed *Streptococcus pneumoniae* and stool culture

revealed *Shigella flexneri*. The *S. pneumoniae* was sensitive to tetracycline, ampicillin, chloramphenicol, penicillin, and erythromycin but resistant to gentamicin. The *Shigella* isolate was sensitive to nalidixic acid and pivmecillinam but resistant to ampicillin and trimethoprim-sulphamethoxazole.

Clinical Management. Immediately after admission the child was given an intravenous injection of 25% glucose and an intravenous rehydration solution was started which contains Na^+ 133 mmol/l, K^+ 13 mmol/l, Cl^- 98 mmol/l, bicarbonate (as acetate) 48 mmol/l, and glucose 5 percent. Ampicillin (200 mg/kg/24hr) and gentamicin (6 mg/kg/24hr) were given intravenously to cover both Gram-positive and Gram-negative organisms. Hyponatraemia (serum Na^+ 129 mmol/l) was treated by replacing the i.v. solution with normal saline (0.9% NaCl) with 5% dextrose. Pivmecillinam was given orally for the treatment of *Shigella flexneri* infection. In addition, vitamin A (200,000 units), zinc acetate, and vitamin B were also given as supportive treatment of malnutrition. On isolation of *S.pneumoniae* from blood, penicillin was started in high doses and ampicillin and gentamicin were stopped. On the second day of admission the child looked more sick and a nasogastric tube was introduced for feeding a high protein milk formula (1 kcal/ml) which provided 80 kcal/kg per day and 3.4 g/kg of protein. On the third day of admission the condition of the child was deteriorating. The oedema of the feet increased, abdomen distended with fluid, bowel sound was poor and rectal prolapse developed. As the patient was hypothermic (rectal temperature $<35.7^\circ\text{C}$) and thrombocytopenic (platelet count 90,000/cmm), a fresh blood transfusion was given. On 5th day of admission another unit of fresh blood was transfused for the same reason. Patient's condition further deteriorated. The child became lethargic, hypothermic (rectal temperature below 35°C), pulseless with poor peripheral perfusion with marked abdominal distention and sluggish bowel sounds. A repeat blood culture was drawn and gentamicin was restarted. This time the child vomited one adult round worm (*Ascaris lumbricoides*) and was treated with a 3-day course of mebendazole. On 6th day, the child again became hypoglycaemic and treated with a bolus of 25% dextrose intravenously. A third unit of fresh blood was transfused. The child's condition was slightly improved and milk-feed was allowed by mouth. On day 7 and 8, there was no further improvement of the child's condition and a 3rd unit of fresh blood was given. On day-11, a repeat blood platelet count was 45,000/cmm and a repeat chest x-ray showed consolidation in right upper lung field. During hospital days 12-13, the general condition of the child further deteriorated, oedema increased, abdomen was further distended, and bowel sound was very sluggish or absent. At this time all investigations were repeated which showed a total

white cell count of 26,000/cmm, neutrophil 70%, band-cell 2%, haematocrit 33%, and platelet 45,000/cmm. Repeat serum Na^+ was 128 mmol/l, K^+ 5.31 mmol/l, Cl^- 96 mmol/l, total carbon dioxide 25.4 mmol/l, total serum protein 49 g/l, creatinine 59 $\mu\text{mol/l}$, and serum albumin 19.6 g/l. At this stage i.v. tobramycin and ampicillin were started to treat probable hospital acquired septicaemia. Bilious materials with altered blood came out through the nasogastric suction. On day 14, the child became critically ill with gasping respiration and distended abdomen with sluggish bowel sound. A repeat blood culture yielded growth of *Escherichia coli* which was sensitive to ceftriaxone, gentamicin, nalidixic acid, ciprofloxacin, and tobramycin. Ceftriaxone was started intravenously. On day 15, the patient's condition was very poor with low volume pulse, gasping respiration, and hypothermia. All resuscitative measures failed and the child died in the night of day 15 in the hospital in spite of adequate antimicrobial treatment and nutritional support.

DISCUSSION ON DIFFERENTIAL DIAGNOSIS

The summary of the clinical findings of this child indicates that the child was severely malnourished and had 5 days of dysentery and fever. She also had pneumonia, ascitis, oedema, bacteraemia due to multiple pathogens, poor peripheral perfusion, hypoglycaemia, hyponatraemia, hypoproteinaemia and leucocytosis with thrombocytopenia. These clinical findings can be broadly categorised into two major entities; viz, symptoms related to malnutrition and symptoms related to infections. The interrelationship between malnutrition and infection is now well known specially in the children of the developing parts of the world. Since this child comes of a poor family, she probably developed gradual protein energy malnutrition (PEM) and became susceptible to infection by multiple pathogens. Although the interaction between malnutrition and infection is well recognized yet the mechanism(s) of how one causes the other is poorly understood. It has been shown that bacterial, viral, and parasitic infections adversely affects nutrition, predominantly through immunologic and metabolic mechanisms (1,2). During infection, there is increased loss of K, Mg, Zn, PO_4 , SO_4 and vitamin A, B_2 , and C. Liver glycogen is rapidly depleted and increased mobilization of nitrogen from muscle takes place for neoglucogenesis with increased urinary nitrogen excretion and muscle wasting. In severe infection increased diversion of nutrients including amino acids from normal metabolic pathways takes place for the synthesis of acute phase protein, such as heptoglobin, C-reactive protein, alpha-1 antitrypsin, and alpha-2 macroglobulins. The child under discussion had multiple bacterial infections due to *S.pneumoniae*, *E.coli*, and *Shigella flexneri*. The last one is known to cause severe protein loss from the gastrointestinal tract and

probably contributed to severe hypoproteinaemia (serum protein 49 g/l) and oedema in this child. Severe protein catabolism due to multiple infections together with food deprivation has caused the child to develop the typical syndrome of Kwashiorkor, a form of PEM characterised by oedema, skin changes, apathy, weakness, enlarged fatty liver, low serum protein, albumin, and minerals. Once the child is malnourished, her ability to fight against infection is significantly reduced. In severe malnutrition both cellular and humoral immunity are depressed. It has been shown by Chandra *et al* that mortality due to measles was 4 times higher in malnourished Indian children (2). Leyton *et al* showed that protein supplementation protects against tuberculosis infection in children (3). In malnourished children duration of Australian antigenemia is increased and skin responses are decreased (4). Thymus atrophy, lymphoid atrophy, and reduction of non-B, non-T lymphocytes as well as reduction of interleukins have all been demonstrated in malnutrition. Malnutrition also adversely affects humoral immunity. It has been shown that IgG, IgM, IgA all are significantly reduced in children with PEM (5). The ability to control bacterial infections through phagocytosis, chemotaxis and neutrophil-mediated actions are also depressed (6). In malnourished children, defects in complement system have been associated with increased susceptibility to bacterial infections.

Another important factor that protects against infection is the breastfeeding. It has been shown that breastfed infants are less susceptible to infections (7). Human breastmilk contains many protective factor including lysozyme, lactoperoxidase, lactoferrin, interferon, leucocytes, and anti-*Staphylococcal* factor. The child under discussion was breastfed for only 3 months in her life and she became increasingly susceptible to bacterial infections.

This child had evidence for Gram-negative sepsis due to *E. coli* as well as *Pneumococcal* bacteraemia. Gram-negative bacteraemia is a serious and life-threatening complication of diarrhoeal illnesses. In a recent report Struelens *et al* have described the importance of Gram-negative bacteraemia in a large group of children treated at this hospital (8). The results indicate that *Enterobacteriaceae* are an important cause of bacteraemia with a case-fatality rate of 29.7% compared to controls (7.8%). The highest risks of death involve children who are less than 1-year old and had Gram-negative bacteraemia with decreased intestinal peristalsis, hypothermia, hyponatraemia, and hypoproteinaemia. The child we are discussing had, unfortunately most of the indicated risk factors which significantly contributed to death. The mechanism of bacteraemia in patients with invasive diarrhoea is not well understood. This child had proven infection due to *Shigella flexneri* which is known to cause severe colonic inflammation, ulceration, and crypt abscesses. Colonic bacterial invasion through the damaged mucosa may be the most probable route for entry

into the blood stream. Clinically, Gram-negative sepsis is characterised by decreased peripheral vascular resistance, pooling of blood, diminished venous return, low cardiac output and low blood pressure. These findings were consistent with the clinical presentation of the child indicating presence of Gram-negative shock in absence of acute volume depletion. In the blood stream, release of bacterial endotoxin and cell wall materials including lipopolysaccharide antigen (core LPS, lipid LPS) lead to the formation of bradykinins, serotonin, complement components, prostaglandins, and endorphins which can bring about the cardiovascular changes seen in patients with septic shock. Sepsis can cause metabolic changes including hypoglycaemia which was seen in this child in several occasions. Hypoglycaemia is probably brought about by inhibition of neoglucogenesis, depletion of glycogen stores, increased glucose utilization, and increased insulin release. However, a recent study at this centre showed no changes in the hormones (insulin and glucagon) but failure of neoglucogenesis was found to be the primary cause of hypoglycaemia in malnourished children with diarrhoeal illnesses (9).

We believe that most of the clinical findings of the child can be explained by the pathophysiologic changes that accompany severe malnutrition and bacterial infections. However, there may be other rare causes which may have to be considered in the differential diagnosis. **Intestinal lymphangiectasis** is a rare congenital obstructive defect of the lymphatics primarily affecting children and young adults. The disease is characterised by protein-losing enteropathy, hypoproteinaemia, oedema, malabsorption, growth failure, dilated lymphatics, chylothorax, chyluria, and chylous ascitis. Final diagnosis is based on histological changes of the dilated lymphatics of the intestine.

Another parasitic infestation to be considered in the diagnosis is the *Ascaris lumbricoides* infection, which is highly prevalent in this region but is a rare cause of oedema, ascitis, and death among children 1-year of age. Recently Hall and Selim demonstrated that 87% Bangladeshi urban dweller were infected with *Ascaris lumbricoides* (10). Heavy *Ascaris* infestation can cause intestinal or biliary obstruction and sometimes is associated with malnutrition. This child once vomited one adult round worm in the hospital and subsequently was treated with a full course of anthelmintic.

DISCUSSION ON POSTMORTEM FINDINGS

Postmortem examination was carried out 11 hours and 35 minutes after the death of this child. On opening the abdomen, approximately 200 ml of thin, turbid fluid was found in the peritoneal cavity which also contained one free floating adult *Ascaris* worm, 10 cm in length. The layer of purulent exudate covered the serosal surface of the rectosigmoid and the pelvic fossae. Mucosal surfaces of stomach and

the small intestine appeared oedematous, mucosa of transverse colon and rectosigmoid showed dark reddish brown discolouration. Eight *Ascaris* worms were found in the small intestine. No perforations were found in the intestinal tract. The liver showed 10 subcapsular abscesses, the largest of which was 2 cm in diameter. One abscess in the liver was found ruptured, through which 3 *Ascaris* worms protruded into the peritoneal cavity. The main bile duct and the major branches of hepatic ducts were filled with many coiled up *Ascaris*. Upper lobe of right lung was collapsed, its lower lobe appeared congested but did not show definite consolidation. Upper lobe of the left lung appeared unremarkable but lower lobe of left lung showed small patches of consolidation. Heart, kidney spleen and adrenals appeared unremarkable.



Fig. 1. Adult *Ascaris lumbricoides* protruding through ruptured liver abscess showing distended and destroyed hepatic ducts.



Fig. 2. Coils of multiple *A. lumbricoides* within liver abscess.

On microscopic examination the liver tissue adjoining the abscess cavities revealed destruction of the hepatic ducts by inflammatory exudate and granulation tissue, in which numerous ova of *Ascaris lumbricoides* were present. Adjoining liver parenchyma showed biliary stasis and sinusoidal

haemorrhage. Section of rectosigmoid showed acute inflammation over the peritoneal surface, in which an ovum of *Ascaris lumbricoides* was found embedded in the inflammatory exudate. Colonic mucosa showed slight mononuclear infiltration only and focal superficial mucosal necrosis was seen in small intestine. Section of right lung revealed collapse, patches of interstitial pneumonia and a patch of fibrinous exudate on its pleural surface. Sections of left lung revealed interstitial pneumonia and *Cytomegalovirus* inclusions. A section through head of the pancreas revealed cross-section of an *Ascaris* impacted in a pancreatic duct. Sections of kidney showed focal acute tubular necrosis and mesenteric lymph node showed lymphoid hypoplasia. The initial pneumococcal sepsis appears to have been treated adequately, since sections of lungs did not reveal alveolar pneumonia. Subsequently, on the 13th hospital day, the patient probably again developed Gram-negative sepsis from the peritonitis which she had developed after the rupture of the liver abscess.

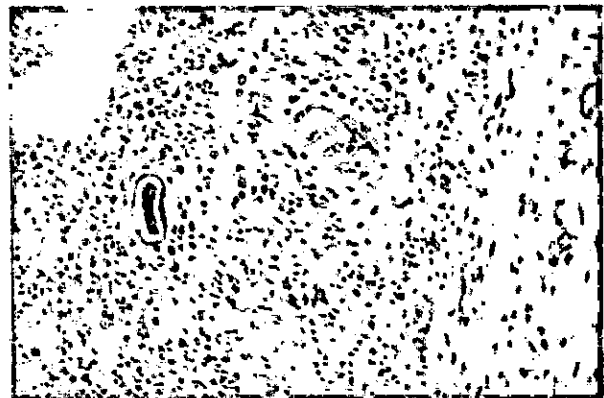


Fig. 3. Ovum of *A. lumbricoides* embedded in the inflammatory exudate on peritoneal surface of rectosigmoid. H & E stain; magnification 66 X.

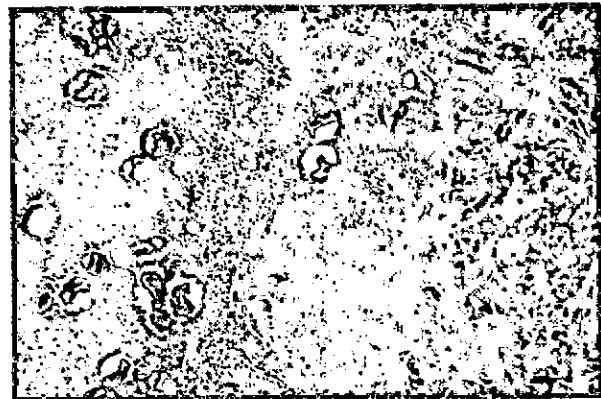

Fig. 4. Ova of *A. lumbricoides* in inflammatory exudate in the wall of destroyed hepatic ducts. H & E stain; magnification 33 X.

Final diagnosis.

1. Peritonitis and sepsis due to rupture of liver abscess caused by impaction of *Ascaris lumbricoides* in hepatobiliary tract.
2. Cytomegalovirus pneumonia.
3. Treated colitis.
4. Kwashiorkor.

Clinicopathological discussion: Ascariasis is a common helminthic infestation of children in the tropical countries and estimates of 7800 million infected people in the world has been reported (11). Although it is highly prevalent the parasite seldom causes severe illness. However, in severely malnourished and immunocompromised children serious life-threatening complications can occur. The life cycle of *Ascaris lumbricoides* is complex. Fertilized eggs develop in warm, moist soil into infective larvae. When these are ingested with contaminated food, the eggs hatch in the intestine, penetrate the intestinal wall and reach portal vein. Through the blood they reach pulmonary alveoli and into the bronchus and trachea and finally swallowed down into the stomach. The worms usually live in the small intestine and the female deposits eggs, about 240,000 per day (12). In the intestine the worms can cause abnormality in the mucosal pattern and malabsorption of nutrients and vitamins (13). However, their definitive effects on nutrition is not clear. *Ascaris* infestations have significant nutritional effects in children and a significant reduction in fat, protein, and vitamin utilization has been reported (14). *Ascaris*-infected children in Bangladesh has been shown to have a significantly lower mean plasma albumin concentration, and loss of mucosal integrity (15). While migrating through the liver and lungs, the larvae can cause inflammatory lesion. Expulsion of adult worms by mouth is not uncommon. Pawloski *et al* (16) reported that 3.3% of Polish population of 580 infected cases vomited worms. Intestinal obstruction has been reported in 2 per 1000 children per year with ascariasis in a rural area of southeastern United States (17). Laparotomies due to complicated ascariasis may constitute as much as 11 percent of all laparotomies carried out in children in the tropics (18). The clinical presentation of ascariasis varies from the relatively mild symptoms to fulminant disease, depending on worm load, site and severity of obstruction, and presence of complications including perforation, gangrene, volvulus, and intussusception. Occasionally the adult worms may migrate from the intestinal lumen and cause obstructive biliary disease. Migrating adults may deposit eggs in the extraintestinal tissues, causing necrosis and granulomatous lesions. Ascariasis should be suspected in children presenting with right upper abdominal

pain not relieved by analgesics, and vomiting of bile-stained gastric contents. Fever, leucocytosis, and jaundice may occur later as complications. The next common complication is the hepatic ascariasis which occurs most frequently in children (19). Piggott *et al* described 38 patients with serious fatal complications due to *Ascaris* (20). Of these 38 patients, 21 had biliary obstruction, 5 had intestinal obstruction, and 5 intestinal perforation. *Ascaris lumbricoides* is a parasite which lives in the small intestine and can migrate into the lumen of vermiform appendix or proximally to the stomach, trachea and bronchi. Migration of the worms into the liver producing pathological changes has not yet been sufficiently described to become a definite clinical entity. Sattar *et al* (21) reported a case of hepatic ascariasis in Bangladesh. This 4-year girl presented with abdominal pain, fever, and enlarged liver. The authors found *Ascaris* eggs in the liver aspirate but no *Entamoeba histolytica*. Rashid, *et al.*, reported a similar case of biliary tract obstruction caused by living and dead *Ascaris* (22). Belding *et al* described migration of adult *Ascaris* into the common bile duct, cystic and hepatic ducts and gall bladder through the ampulla of Vater associated with inflammation and obstruction (23). Thannisch *et al* (24) claimed on the basis of findings of liver biopsies that the migration of adult *Ascaris* caused hepatic abscess. Khaleque *et al* (25) demonstrated adult *Ascaris* and their eggs associated with liver abscess and chronic inflammatory changes in the liver during postmortem examination. Adult worms were also found in the pancreatic duct and in the bronchus. The bacteria carried by the worms during travel cause suppurative cholangitis and fibrocaseous nodules in the liver containing *Ascaris* eggs. Chaudhury *et al* (26) in Bangladesh described 3 patients who had intestinal obstruction due to *Ascaris* which were removed at surgery. These cases were young adults and presented with acute abdominal pain, vomiting, nausea, and abdominal distention. Similarly Rouf *et al* (27) described *Ascaris* associated surgical complications in a group of Bangladeshi children. The authors reported that intestinal obstruction was the major complication (81.5%), followed by perforation of the small intestine (7.4%) and appendicitis (7.4%), biliary obstruction was the least in this series. The authors reported that among the 22 patients of *Ascaris*-obstruction, 13 were operated and 9 were treated conservatively. There was one death among the later treatment group. In our child under discussion an adult *Ascaris* was found free in the peritoneal cavity, though there was no evidence of intestinal perforation. It may be that the perforation in the intestine has been sealed by omentum or that the worm came out through the liver by rupturing the liver capsule. Chronic granulomatous changes in the liver along with multiple *Ascaris* abscesses have actively destroyed liver tissues including the capsule which has given way to the migrating *Ascaris*. Interestingly, however,

there was no clinically evident jaundice in this child; suggesting that even with heavy *Ascaris* load in the liver, bile flow was not completely obstructed. Adult *Ascaris* can cause obstruction at any sites, and masses of worms obstructing the small intestine usually at the ileal level causing volvulus, intussusception, gangrene, and perforation; all have been described (28,29). In India, 40 out of 109 patients with biliary and pancreatic diseases had evidence of ascariasis as an aetiological factor (30).

The mechanism of intestinal perforation by the *Acaris* is not well understood. It is believed that it is the mature worm which damage the intestinal epithelium by some yet unknown mechanism (31). Others suggested that the toxic products of disintegrated worms are responsible for the damage to the intestinal wall (32).

Diagnosis of ascariasis can be simply made by seeing the characteristic eggs in the stool under the microscope. Visible expulsion of adult worms in the stool or through the mouth also confirms the diagnosis. Adult worms can be seen during gastrointestinal endoscopy or abdominal surgery. Sometimes worms can be seen during radiographic examination of the small intestine. *Ascars* larvae may be found in the sputum or gastric washings. Intestinal ascariasis can be treated with any of the modern anthelmintics including piperazine, levamisole, pyrantel, and benzimidazole carbamate (mebendazole), these drugs produce a cure rate of 80% to 100%. Effective treatment of extraintestinal ascariasis has not been well evaluated in paediatric patients.

QUESTION ANSWER SESSION

Q: Dr. Rabbani. The worms that were found in the liver appear to be small compared to those recovered from well-nourished children. Is it possible that the host malnutrition also affects the growth and development of the parasite?

A: Dr. M. Islam. This is an interesting aspect of host-parasite relationship that has not been adequately studied and we do not have an answer at hand.

Q: Dr. Amal Mitra. My question relates to the proper timing of anthelmintic treatment to be given in diarrhoeal children who also have *Ascaris* infestation. At this centre the usual practice is to wait until the diarrhoea is resolved. The question is "can we treat *Ascaris* during acute diarrhoea?". I have successfully treated ascariasis during the acute illness without any problem. If treatment is prescribed at the time of discharge, the patient may not eventually get it.

A: Dr. A.N. Alam. Yes, we usually give treatment during the early convalescent period because worms may be vomited which may interfere with drinking of

ORS. But the treatment can safely be given in diarrhoeal children under careful clinical observations.

Comments: Dr. S.K. Roy. During an epidemic we gave anthelmintic drug to children with diarrhoea and observed that the children developed severe vomiting that interfered with oral rehydration therapy. We subsequently decided to treat children during the early convalescent period.

Q: Dr. Nahrina. Could this child with heavy *Ascaris* infestations involving liver have benefited if treatment for ascariasis had been given early in course of the disease?

A: Prof. K.A. Monsur. This child probably had prolonged malnutrition and advanced hepatic ascariasis. I strongly doubt that treatment given at this stage would be of benefit to the patient.

Comments: Brig. M.R. Chowdhury. This is an interesting case of PEM complicated by fatal *Ascaris* infestation. Ascariasis is an important public health problem in this country and in the army about 50% individuals are infected. I think the role of ascariasis in childhood malnutrition should be adequately assessed.

Q: Dr. Rabbani. *Ascaris* is known to cause peripheral eosinophilia and eosinophilic pneumonitis (Loeffler's Syndrome). Dr. Islam did you find any such lesion during the postmortem examination?

A: Dr. M. Islam. No, we did not find such changes in the lung tissue.

Q: Dr. D. Mahalanabis. How long do you think the worms were in the liver to cause such destructive changes?

A: Dr. M. Islam. The worms must have been in the liver for quite sometime, not less than a week, I guess.

Q: Dr. Samir Nath. Dr. Azad has studied the problem of hypoglycaemia in children with diarrhoeal diseases. I want to know what percentage of patients developed persistent hypoglycaemia.

A: Dr. A.K. Azad. Glucose homeostasis in diarrhoeal children is a complex process. Results of our study (9) indicate, in malnourished children there is a defect in neoglucogenesis in the liver due to inadequate availability of substrate such as alanine and other protein. We did not find any significant changes in the hormones (insulin and glucagon). Low dietary intake and increased metabolic demand also constitute important factors for developing persistent hypoglycaemia.

Q: Dr. Kabir. Whether the *Ascaris* eggs that were found in the liver migrated from the intestine or deposited by the mature worms in the liver?

A: Dr. Rabbani. *Ascaris* eggs are usually laid in the liver by the adult worms. The eggs by itself cannot be transported from the intestine unless hatched into migrating larvae.

Q: Dr. R. Islam. Can the hatching larvae migrate through the portal vein instead of systemic circulation?

A: Dr. Rabbani. There is evidence in the literature that larvae can migrate from the intestine through the systemic veins, portal veins, as well as the lymphatics.

Q: Dr. Asma Islam. Since the child vomited one adult worm, could it be associated with the fatal condition of the child?

A: Dr. Rabbani. *Ascaris* is a known but rare cause of intestinal and biliary obstruction and has been associated with malnutrition in the children. However it is difficult to ascertain whether the *Ascaris* was the primary cause of the fatal illness.

REFERENCES

1. Murthy KK and Suskind RM. Malnutrition and immune response. In: Lebenthal E (Ed). Textbook of gastroenterology and nutrition. Raven Press, 1990, New York. pp 545.
2. Chandra RK. Immunocompetence in malnutrition. *J Pediatr* 1972;81:1194-200
3. Leyton GB. Effects of slow starvation. *Lancet* 1946;2:73-9.
4. Suskind RM, Olson LC, and Olson RE. Protein calorie malnutrition and infection with hepatitis-associated antigen. *Pediatrics* 1973;51:525-30.
5. Alvarado J and Luthringer DG. Serum immunoglobulins in oedematous protein calorie malnourished children. Studies in Guatemalan children at INCAP. *Clin Pediatr* 1971;10:174-9.
6. Edelman R, Suskind R, Olson RE, Srisinha S. Mechanism of defective delayed cutaneous hypersensitivity in children with protein calorie malnutrition. *Lancet* 1973;1:506-8.
7. Glass RI, Svennerholm A-M, Stool BJ. Protection against cholera in breast-fed children by antibodies in breastmilk. *N Eng J Med* 1983;308:1389-92.
8. Strulens MJ, Bennish ML, Mondal G, Wojtyniak BJ. Bacteremia during diarrhea: incidence, etiology, risk factors, and outcome. *Am J Epidemiol* 1991;133:451-9.

9. Bannish ML, Azad AK, Rahman O, Phillips RE. Hypoglycemia during diarrhoea in childhood; prevalence, pathophysiology, and outcome. *N Eng J Med* 1990;322:1357-63.
10. Hall A, Anwar KS, Tomkins AM. Intensity of reinfection with *Ascaris lumbricoides* and its implications for parasite control. *Lancet* 1992;339:1253-7.
11. Editorial. *Lancet* 1985;2:1284.
12. Sinniah B Daily egg production of *Ascaris lumbricoides*. The distribution of eggs in feces and the variability of egg counts. *Parasitology* 1982;84:167-75
13. Cook GC. Hypolactasia: geographical distribution, diagnosis and practical significance. In: Chandra RK, editor. Clinical reviews in tropical medicine. Vol 2. New York: Plenum Press, 1984;117-39.
14. Nesheim MC, Pawloski ZS. Ascariasis and its prevention and control. London: Taylor and Francis, 1989;87-100.
15. Northrop CA, Lunn PG, Evans WM. Plasma albumin concentrations and intestinal permeability in Bangladeshi children infected with *Ascaris lumbricoides*. *Trans R Soc Trop Med Hyg* 1987;81:811-5.
16. Pawloski ZA. Ascariasis. *Clin Gastroenterol* 1978;7:157-78.
17. Blumenthal DS, Schultz SG. Incidence of intestinal obstruction in children infected with *Ascaris lumbricoides*. *Am J Trop Med Hyg* 1975;24:801-5.
18. Crompton DWT, Nesheim MC, Pawloski ZS. Prevention and control of Ascariasis. London: Taylor and Francis (in press).
19. Maki T. Surgical diseases due to *Ascaris lumbricoides*. In: Morishita K, Komiya Y, Matsubayashi H, editors. Progress of medical parasitology in Japan. Tokyo: Tokyo Meguro Parasitological Museum, 1972;vol. 4:221-70.
20. Piggot J, Hansbarger EA, Neafie RC. Human ascariasis. *Am J Clin Path* 1970;53:223-4.
21. Sattar AMB, Zaman MM. Hepatic Ascariasis. *Bangladesh Med J* 1973;2:67-8.
22. Rashid MA. *Ascaris* in the biliary system. *Bangladesh Med J* 1991;20:47-9.
23. Belding DL. Textbook of clinical parasitology. New York: Allpeton, 1952.
24. Thanniesh G. *J Pediatrics* 1958, 53:603
25. Khaleque KA, Moazzem MG, Ibrahim M. *J Trop Med Hyg* 1960, 1:3
26. Choudhury DER. Surgical problems with *Ascaris lumbricoides*. *Syhet Med J (Bangladesh)* 1985;7:17-9.
27. Rouf HMA. Ascariasis and its surgical complications in children. *Bangladesh J Child Hlth* 1990;14:8-11.
28. Cook GC. Intestinal parasitic infections. Current Opinion *Gastroenterology* 1989;4:113-23.
29. Odaibo SK, Awogun LA. Small intestinal perforation by *Ascaris lumbricoides*. *Tran R Soc Trop Med Hyg* 1988;82:154.
30. Khuroo MS, Zargar SA. Biliary ascariasis: a common cause of biliary and pancreatic disease in an endemic area. *Gastroenterology* 1985;88:418-23.
31. Ihekweba FN. *Ascaris lumbricoides* and perforation of the ileum: a critical review. *Br J Surg* 1979;66:132-4.
32. Louw JH. Abdominal complication of *Ascaris lumbricoides* infestation in children. *Br J Surg* 1966;53:510-21.

GH Rabbani; Hassan Ashraf; Moyenu Islam;
A.K. Azad; ICDDR,B.